

# Chemical composition and anti-arthritic activity of *Anacyclus valentinus* extract on adjuvant-induced arthritis in rats

Khadidja Side Larbi<sup>1</sup>, Boumediene Meddah<sup>1</sup>, Hamza Belkhodja<sup>1</sup>, Asmaa Belmimoun<sup>1</sup>, Khaled Slimani<sup>2</sup> and Pascal Sonnet<sup>3</sup>

<sup>1</sup>Bioconversion Research Laboratory, Engineering Microbiology and Health Safety, Faculty of SNV, University of Mascara, Algeria

<sup>2</sup>Department of Veterinary Sciences, University of Ibn Khaldoun, Tiaret, Algeria

<sup>3</sup>Laboratories of Glucides-Team Thera- FRE-CNRS 3517, Faculty of Pharmacy, University of Picardie, Amiens, France

**Abstract**— *Anacyclus valentinus* L. is a common annual plant in Algeria, known for her various therapeutic effects. In addition, the plant is used as a food condiment. We reported our investigations on the chemical compositions and the antiarthritic activity of methanolic extract of *A. valentinus* (MEAV). The polyphenol extraction by maceration with methanol (80%) gave yields of 17.82%. The identification by LC-MS and colorimetric assays revealed the wealth of methanolic extracts on phenolic compounds including flavonoids (52.15 mg Equ/g) and lactones.

Acute oral toxicity of extract was performed in line with OECD guidelines and the lethal dose 50 was assessed greater than 2500 mg/Kg. Regarding the anti-arthritic power, rheumatoid arthritis was induced by Freund's adjuvant in rats. The methanolic extract of *A. valentinus* presented a largest effect with weight gain, an arthritic score, thymus indices; spleen and serum parameters close to those of the control. The extract also inhibited edema and restored cartilage structure.

**Keywords**— *Anacyclus valentinus*, Arthritis, diclofenac sodium, Freund's complete adjuvant, paw volume

## I. INTRODUCTION

Rheumatoid arthritis (RA) is a chronic and systemic autoimmune joint disease characterized by pain, swelling and inflammation of peripheral joint and destruction of articular tissues and restricted joint movement [1]. RA is one of the most common inflammatory disorders affecting approximately 0.5–1.0% of global adult population [2]. The systemic ramifications of the disease, apart from morbidity and mortality, include cardiopathy, nephropathy, vasculopathy and pulmonary and cutaneous disorders [3].

Conventional medicines used for RA include non-steroidal anti-inflammatory drugs (NSAIDs), disease-modifying anti-rheumatic drugs (DMARDs),

biological response modifiers, and corticosteroids [4]. However, these treatments are accompanied by frequently toxicity and severe side effects. Therefore, more patients look for natural agents with relatively less side effects. Plant derived drugs serve as lead molecules to develop more effective and less toxic medicines [5].

*Anacyclus valentinus* is a medicinal plant belonging to the family *Asteraceae*, locally known as «Guertoufa» [6] and mainly distributed in the Mediterranean basin and in northern Africa [7]. The plant is widely used in folk medicine for treatment of diverse diseases, such as diabetes [8] and cholesterol [9]. *A. valentinus* has an inhibitory effect on bacteria [10] and fungal [11]. It is also used in some parts of the country as a food condiment. Phytochemical studies on plants belonging to the genus *Anacyclus* made known the presence of terpenoids, steroids, coumarin and flavonoids like quercetin and luteolin [12]. Although the plant possesses many potential therapeutic activities in traditional system and containing rich phytochemical constituents, no work has been still done about the anti arthritic activity. Taking these facts into considerations the present study made an attempt to study the chemical composition and to evaluate the anti arthritic activity of methanolic extract of *A. valentinus* against Freund's complete adjuvant induced arthritis in experimental rats.

## II. METHODOLOGY

### 2.1. Plant material

The areal parts of *Anacyclus valentinus* were collected on October 2013, from local area of El- Bayadh, Algeria. The plant material was identified and authenticated by botanists from Department of Biology, University of Mascara, Algeria. The plant was shade dried powdered in grinder and passed through sieve of mesh size N°40.

## 2.2. Preparation of extract

10 g of dried powder was macerated with 80% methanol at room temperature for 24h. The plant residue was re-extracted with addition of 80% methanol, and filtered again after 24 h. Combined filtrates were concentrated by evaporation, dried in desiccator and were stored in airtight containers until usage [13].

## 2.3. Analysis of extract

### 2.3.1. Total phenolic content determination (TPC)

The total phenolic content of the extract was determined by the Folin - Ciocalteu method [14]. Briefly 200 µl of the extract was added to 1000 µl of Folin-Ciocalteu reagent (diluted to 10% in distilled water) and 800 µl of sodium carbonate at 7,5 %. The mixture was incubated at room temperature for 30 minutes. The absorbance was measured at 760 nm. Gallic acid in the concentration range of 0-170 µg/ml was used as standard for construction of calibration curve. The total phenolic content was expressed as mg/g in terms of gallic acid equivalents (GAE).

### 2.3.2. Total flavonoid content determination (TFC)

Aluminum chloride colorimetric method was used for estimation of total flavonoid content [15]. 500 µl of extract was mixed with 1500 µl of distilled water, methanol, 150µl of sodium nitrite (6%). After 5min, 150 µl ml of aluminium chloride (10%) was incorporated and set aside at room temperature for 6 min. The absorbance of the reaction mixture was measured at 510 nm with ultraviolet (UV) visible spectrophotometer. The total flavonoid content was expressed in terms of mg/g in terms of quercetin equivalents (QE).

### 2.3.3. LC/MS analysis

The identification of the phenolic compounds from *A. valentinus* was carried out using liquid phase chromatography coupled with mass spectrometry (LC-MS). The methanolic extract was accurately weighed, and dissolved in methanol. 5.0 µL of sample was injected into Shimadzu LC/MS chromatography equipment. LC-MS analysis was performed on a Phenomenex Luna 3u C18 column, with UV detector. The mobile phase consisted of ultra-pure distilled water and acetonitrile. The solvent A consists of 50% water + 50% acetonitrile, while the solvent B is composed of 25% water + 75%. The flow rate was 0.4 mL/min. The column temperature was set at 40 ° C.

## 2.4. Drugs and chemical reagent

Diclofenac sodium was purchased from Pharmacy (Mascara, Algeria). Freund's complete adjuvant agent

(FCA) (Sigma Aldrich), CRP and FR kits (Spinreact) were obtained from the university.

## 2.5. Animals

Healthy adult male albino rats of Wistar strain "*Rattus norvegicus*" (weighing 150 – 200 g) were used. The experimental procedures and protocols were carried out in accordance with ethical guidelines. Animals were provided by the Experimental Station of the University of Mascara/Algeria. They were housed under standard conditions of temperature ( $24 \pm 2$  °C) with a 12:12 light: dark cycle and relative humidity (50 - 60 %). The animals were given standard diet and water *ad libitum*.

## 2.6. Acute toxicity

Acute oral toxicity study of methanolic extract of *A. valentinus* was performed in line with OECD guideline 423[16].

## 2.7. Induction of arthritis

Adjuvant arthritis was induced as described by [17]. Briefly, animals were injected intra-plantar with 0.1 ml of Complete Freund's Adjuvant (CFA) into the left hind paw of each rat. This consists of *Mycobacterium butyricum* suspended in heavy paraffin oil. Methanolic extract (300mg/Kg) and diclofenac sodium (20mg/Kg) were administered to rats in the various groups. For the comparison, two control groups were used arthritic and non-arthritic controls or vehicle control.

## 2.8. Drug administration

Two sets of experiments were performed. In the first set of experiments (preventive protocol), the effect of drugs was investigated when given 2h before induction of arthritis. The animals were grouped as follow: **Group I:** arthritic control; **Group II:** non-arthritic control (Receiving 10 ml / Kg of sterile physiological water); **Group III:** treated with diclofenac sodium; **Group IV:** pre-treated with methanolic extract of *A. valentinus* (MEAV).

In the second set of experiments, effect of the drugs on established arthritis (curative protocol) was studied. Drugs were administered on day 9 after the induction. The animals were randomly grouped as follow: **Group I, Group II and Group III** are the same as for the previous test; **Group IV**": treated with MEAV.

## 2.9. Parameter assessment

### 2.9.1. Paw swelling

The pad thicknesses of the injected paw were measured before and every other day after FCA injection using a calliper. The paw swelling at each time point was expressed as an increase in the footpad thickness (mm)

[18]. For groups pre-treated, measurements were taken on the day of induction on the 5th, 10th and 15th day of treatment. While, for animals subjected to curative tests, the thickness of the paw was determined on the day of induction, on the 1st, the 7th and the 15th day of treatment.

### 2.9.2. Arthritic index

At the end of the experiments, morphological feature of arthritis was monitored, using the criteria as indicated in "TABLE 1" for each animal. The scores for each paw were then added to get the total arthritic index. The average of treated animals is compared with the control group [19].

Table.1: Shows the scores of arthritic index

Lesion site	Nature of lesion	Score
Ears	Absence of nodules and ridness	0
	Presence of nodules and ridness	1
Nose	No swelling of connected tissue	0
	Intensive swelling of connected tissue	1
Tail	Absence of nodules	0
	Presence of nodules	1
For paws	Absence of inflammation	0
	Inflammation at least 1 joint	1
Hind paws	Absence of inflammation	0
	Slight inflammation	1
	Moderate inflammation	2
	Marked inflammation	3

### 2.9.3. Measurement of body weight

The body weight of rats was measured regularly using an analytical balance. The initial weight and final weight of each group were recorded.

### 2.9.4. Thymus index and spleen index assay

At the end of experiments, the animals were sacrificed and thymus and spleen were promptly removed and weighed. The indexes of thymus and spleen were expressed as the ratio of thymus and spleen wet weight versus body weight (mg/g), respectively [20].

### 2.9.5. Blood analysis

Blood samples were collected; centrifuged and supernatant serum was collected. Different parameters were estimated like alkaline phosphatase marker for bone destruction (ALP) [21], rheumatoid factor and C-reactive protein marker of inflammation. These latter were measured by latex agglutination method. Values were expressed as IU/l, IU/ml and mg/L respectively.

### 2.9.6. Radiographic analysis

For radiological studies, the affected paws of experimental rats were removed and preserved in 10% formalin. X-ray images were taken for these paws, and checked for the soft swelling, bony erosions and narrowing of the spaces between joints [22].

### 2.10. Statistical analysis

All the data are presented as mean  $\pm$  SD. Statistical analysis was performed with ANOVA. *P* values below 0.05 ( $p < 0.05$ ) were considered statistically significant.

## III. RESULTS

### 3.1. Total phenolic content and flavonoid content

Total phenolic and total flavonoid content of the methanolic extract is shown in table 2. Following the table, MEAV which gave a yield of 17.82 % is very rich in phenolic compounds, especially flavonoids which occupy 45.16% of the totality of the phenolic compounds.

Table.2: Yield, total phenolic content and total flavonoid content of methanolic extract of *A. valentinus*

Yield (%)	TPC (mg GAE/g)	TFC (mg QE/g)
17.82 $\pm$ 0.49	115.47 $\pm$ 0.13	52.15 $\pm$ 0.78

### 3.2. LC-MS analysis of MEAV

The chemical composition of MEAV was further investigated by LC-MS analysis (Fig.1, Table 3). The table showed the richness of MEAV in flavonoids. Many compounds have characteristic spectra of flavonols (kaempferol, quercetin, myricetin), flavones (apigenin, luteolin) and flavanols (catechin). These results confirm the colorimetric analysis. The analysis also revealed the presence of derivatives of phenolic acids (sinapic acid, ferulic acid- $\beta$ -glucoside), sesquiterpenes (lycoperodine) and derivatives of thymol (9,10-dihydroxy-8-methoxy thymol).

Date Acquired: 10/06/2015 11:28:58  
 Vial#: 61  
 Injection Volume: 2  
 Data File: AV0001.kcd  
 Method File: Injection directe-75%β-pos-neg-1000.lcm

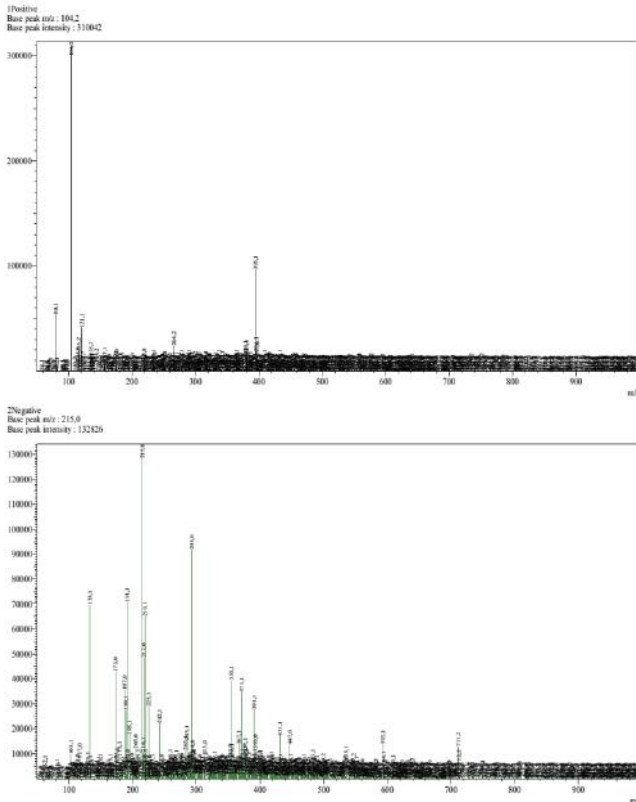


Fig.1: LC-MS-ESI spectrum in positive (up) and negative (low) form of MEAV

Table.3: Identification of MEAV by LC-MS

Pic N°	m/z Ions +/-	Possible identification
4	266,2	Apigenin
1	/133,1	malic Acide
2	/173,0	Ascorbique Acide
3	/187,0	azelaïque Acide
4	/189,1	Catechin
5	/215,0	Lycoperodin 1
6	/217,0	9,10-dihydroxy-8-methoxy thymol
8	/225,1	sinapic Acide
10	/355,1	β-glucosid ferulic Acide
11	/371,1	Myricetin mono-acetate Di hydroxy-tetra methoxy flavone
13	/431,1	Apigenine -7-O- glucoside Kaempferol -3-O- rhamnoside
14	/447,0	Luteolin 3-O-β- glucopyranoside Quercetin 3-O- rhamnoside

### 3.3. Acute oral toxicity

There was neither change in behavioral pattern or any sign of toxicity during the observations up to 14 days. In addition, no mortality was recorded, the LD<sub>50</sub> is therefore

assumed to be greater than 2500 mg/Kg (the biological evaluation was carried out at doses between 200 and 2500 mg/kg). We can conclude that MEAV is safe when administered orally.

### 3.4. Effect of methanolic extract on adjuvant induced arthritis

#### 3.4.1. Paw swelling

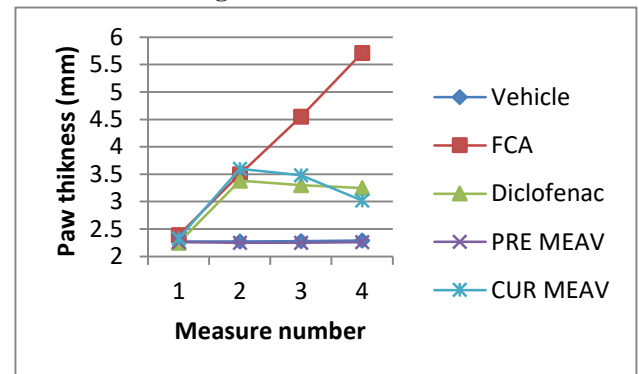


Fig.2: Effect of methanolic extract of *A. valentinus* (MEAV) on paw swelling

Paw swelling is one of the major factors in evaluating the degree of inflammation and therapeutic efficacy of the drug. Rats injected with FCA (group II) showed a significant increase in paw volume when compared to the normal rats (group I). Pre-treatment with MEAV at the dose of 300 mg/kg inhibited the formation of edema. However, the curative treatment with extract and diclofenac showed a significant reduction in rat paw thickness when compared with the group II (Fig.2).

#### 3.4.2. Arthritic index

As shown in figure 3, after FCA immunization, the rats showed a significant ( $P < 0.05$ ) increase of arthritis index. However, pre-treatment and treatment with MEAV at 300mg/Kg and diclofenac at 20 mg/kg significantly diminished the arthritis index compared with FCA group. Noting that, the lowest index was recorded in rats receiving MEAV as a preventive measure.

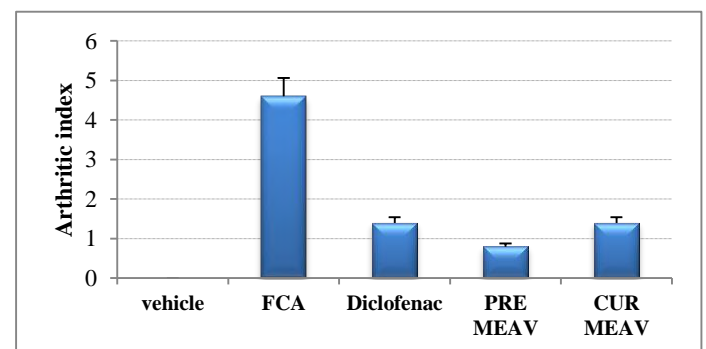


Fig.3: Arthritis index in rats receiving diclofenac and MEAV

### 3.4.3. Measurement of body weight

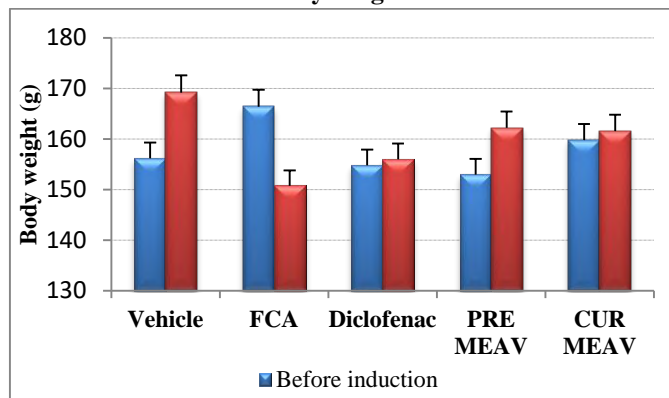


Fig.4: Mean changes in body weight

The relationship between the extent of joint inflammation and the weight loss were investigated. As shown in figure 4, the average body weights of the rats receiving normal saline (group I) was increased normally with a gain of 13g. On the other hand, a massive and significant weight loss appears in arthritic rats. However, administration of different drugs significantly attenuated body weight loss. They are ranked in descending order as follows: PRE MEAV > CUR MEAV > Diclofenac.

### 3.4.4. Thymus index and spleen index assay

The index of thymus and spleen was assayed the day of sacrifice. Results report an increase in thymus and spleen index of FCA control group compared to normal control group. There was significantly (< 0.05) reduction of index of thymus and spleen in MEAV treatments groups (Table 4). Diclofenac treatment also significantly decreased the spleen index and thymus index.

However, the most important result was registered for MEAV preventive treatment compared with normal group.

Table.4: Effect of MEAV on immune organs in arthritic rats

	Thymus Index	Spleen Index
Vehicle	0.683 ± 0.101	2.320 ± 0.212
FCA	1.295 ± 0.131	3.387 ± 0.151
Diclofenac	0.839 ± 0.128	2.732 ± 0.237
PRE MEAV	0.690 ± 0.177	2.478 ± 0.594
CUR MEAV	0.741 ± 0.117	2.751 ± 0.278

### 3.4.5. Blood analysis

Table 5 depicts the effect of MEAV on levels of blood marker in arthritic rat serum. A significant increase in the levels of ALP, RF and CRP was observed in arthritic rats. The administration of MEAV (300mg/kg) and diclofenac

(20mg/kg) significantly decreased all these parameters compared to FCA control (< 0.05).

Table.5: Effect of MEAV on serum parameters in arthritic rats

	ALP (UI/L)	RF (UI/ml)	CRP (mg/L)
Vehicle	79.65 ± 3.90	8 ± 0	6 ± 0
FCA	114.17 ± 4.01	57.60 ± 14.31	38.40 ± 13.14
Diclofenac	93.48 ± 8.10	14.40 ± 10.43	7.20 ± 2.68
PRE MEAV	77.29 ± 8.44	9.60 ± 3.57	6 ± 0
CUR MEAV	81.28 ± 6.24	11.20 ± 4.38	7.20 ± 2.68


### 3.4.6. Radiographic analysis

The radiographic images of the joints of all groups of rats are shown in Fig.5. The articulation of normal control group presented a normal opacity, joint space and cartilage appeared to be normal.

As shown in this figure, it is evident from the radiographic images that adjuvant treated rats (group II) developed periosteal reaction, irregular joint space with opacity essentially concentrated at the level of the femoral condyle. The presence of knee arthritis (inflammation of the knee joint), joint instability and cartilage lysis were also observed.

Although diclofenac treatment (group III) reduced inflammation and improved the metabolic function of rats, the radiographic image of joint showed opacity essentially concentrated at the tibial condyle. A lysis of the articular cartilage is also observed.

In the extracts pre-treated group (group IV), the joint space appeared normal, no periosteal reaction was observed and joints appeared to be normal. Whereas, a slight bone lysis was determined at the joint of MEAV-treated rats (group IV<sup>o</sup>). This joint had a radiographic appearance of normal opacity.



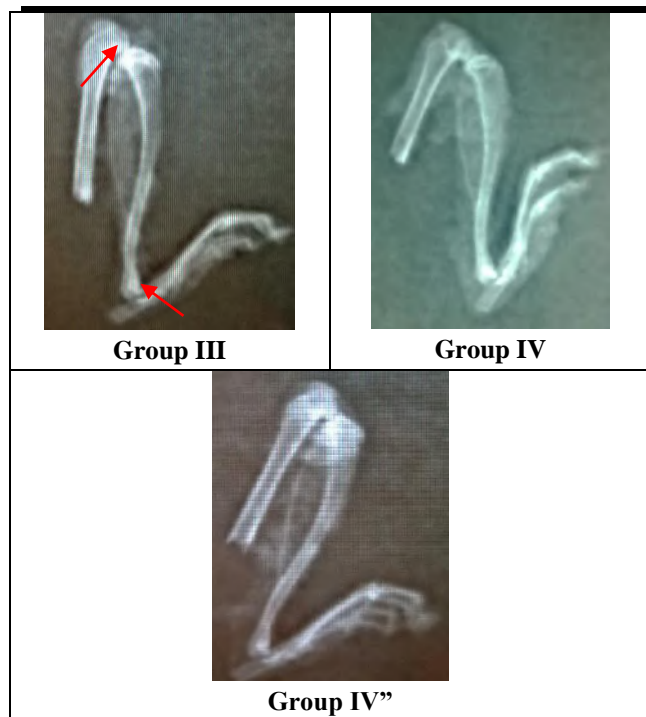


Fig.5: X-ray photographs of left hind paw of each group of rats

#### IV. DISCUSSION

Adjuvant-induced arthritis is commonly used in experimental model for preclinical studies. Due to its short duration of testing, easy measurement and similarities to human RA, this model has been used frequently to evaluate therapeutic agents. In this model, rats developed a chronic swelling in multiple joints with influence of inflammatory cells, erosion of joint cartilage and bone destruction and remodelling [23]. These inflammatory changes eventually result in the complete destruction of joint stability and mobility in the arthritic rats. Also, soft tissue swelling around the ankle joints was appeared during the progress of arthritis in FCA injected rats, which was considered as oedema of the exacting tissues.

Paw swelling is a parameter of measuring the anti-arthritis activity of various drugs. The visual arthritic index was used to evaluate the severity of arthritis. The determination of paw swelling and arthritic index is simple, sensitive, and quick procedure for evaluating and assessing the degree of inflammation, the therapeutic and curative effects of drugs [24]. In the present study, treatment with MEAV markedly reduced paw swelling and arthritic index induced by FCA compared with FCA group. We further confirmed its protective effect. In fact, the preventive treatment gave results close to those of the normal control group.

Progression of disease status and response to anti-inflammatory therapy are indirectly linked with change in body weight. RA is associated with weight loss, known as

rheumatoid cachexia which leads to the decreased physical activity, muscle strength and decreased daily performance [25]. Decrease in body weight was attributed to reduced absorption of  $^{14}\text{C}$ - glucose and  $^{14}\text{C}$ -leucine in rat's intestine [26]. In the present investigation, the FCA treated rats showed less body weight gain as compared with diclofenac, extract pre-treated and extract treated arthritic rats. Thus, body weight gain may be due to the restoration of the absorption capacity of the intestine.

The spleen is a vital organ which serves as the available source of cells and antibody formation, known to be involved in immunological response in adjuvant arthritis. The RA model is an immune hyper-functional model, and marked splenomegaly, and lymphoid hyperplasia were associated with RA [27]. On the one hand, the increase in the weight of the spleen occurs following the release of the cytokines causing a perturbation of the histology of this organ. On the other hand, the variation in thymus weight is due to the suppression or imbalance of the immune system [28]. In the present study, it was found that MEAV significantly decreased the spleen index and thymus index induced by FCA compared with FCA group. This finding suggests that the extract may help in the recovery of the hyper-functioning of immune organs without causing damage.

Cytoplasmic cellular enzymes, such as alkaline phosphatase (ALP) are present in the body, but especially in the liver, bone, intestine, kidneys and white blood cells. The cellular localization of these enzymes assigns them a certain activity in the transfer of phosphoric esters through the membranes. They are involved in intestinal absorption and in the ossification process [29]. The attainment of the above-mentioned organs causes the liberation of ALP [30]. A significant ( $P < 0.05$ ) reduction of ALP level was observed after administration of MEAV (300 mg/kg).

Serum rheumatoid factor (RF) is the immunological expression of an individual's immune system reaction to the presence of an immunoglobulin molecule that is recognized as "non-self." This response results in the presence of immune complexes. These, in turn, bind complement and may eventually lead to synovium, cartilage, and bone destruction. Higher the levels of serum rheumatoid factor, higher are the development of inflammation [31]. *A. valentinus* pre-treated and treated animals showed significantly lesser serum RF when compared to disease control animals.

CRP is an acute-phase protein and has been identified as an important biomarker for various inflammatory and degenerative diseases. The increment of this protein is due to a rise in the plasma concentration of IL-6, which is produced predominantly by macrophages [32]. Freund's adjuvant induced arthritis rats increased the CRP level as

evidenced in the inflammatory process. A significant ( $P < 0.05$ ) reduction of CRP level was observed after administration of MEAV, suggested that decreased the inflammatory reactions.

Radiographic changes in RA are useful indicative measures which specify the severity of the disease. Soft tissue swelling, bony erosions and narrowing of joint spaces can be observed [33]. The observed changes in radiographic findings can be attributed to positive benefits provided by the methanolic extract of *A. valentinus* on the inflammatory mechanisms in the joint tissues.

It is well known that diclofenac had the anti-inflammatory and analgesic activity and often used to cure rheumatoid arthritis. However, this drug only inhibits primary response; do not affect the second response and immune function. In addition, it has obvious side effect and toxicity. Among all tests, the pre-treatment by MEAV proved to be the most effective in chronic inflammation when compared to the other groups. Its action is probably through the inhibition of the production of cyclooxygenase and prostaglandins. The extract, also has an immune-protective effect. In fact, several species of the Asteraceae family are known for their anti-inflammatory effect [34, 35]. These could be attributed to the phenolic constituents present in the plant detected after phytochemical analysis.

Quercetin, myricetin, kaempferol and apigenin identified in the extract have an effect on the synthesis of cyclooxygenase and lipoxygenase [36, 37]. Luteolin 3-O- $\beta$ -glucopyranoside also identified has an inhibitory effect on the synthesis of thromboxanes and consequently on the synthesis of the main arachidonic acid actor of the pro-inflammatory process [38].

## V. CONCLUSION

The results obtained in the present study indicates that phenolic compounds of *A. valentinus* not only directs towards the control of arthritis progression and/or the inflammation associated with joint synovitis, but also prevents cartilage and bone destruction of the arthritic joints. Extracts of *A. valentinus*, may have great potential as an alternative to the therapeutic agents currently available for treatment of RA. However, there is need to isolate and characterize the active compounds responsible for the observed anti-arthritic activity.

## ACKNOWLEDGEMENTS

The authors wish to thank all the individuals and institutions who made this survey possible.

## REFERENCES

[1] L. Klareskog, A.I. Catrina, S. Paget (2009). Rheumatoid arthritis. *Lancet* 373, 659–672.

- [2] P. Patel, D. Patel, N. Patel (2012). Experimental investigation of anti-rheumatoid activity of *Pleurotus sajorcaju* in adjuvant-induced arthritic rats. *Chin J Nat Med*; 10:0269–74.
- [3] D.K. Praveen, M. Suchita (2013). Herbal sources of anti-arthritic potential: a comprehensive review. *Int. J. Pharm.* 4, 88–92.
- [4] N.J. Gullick, D.L. Scott (2012). Drug therapy of inflammatory arthritis. *Clin Med*; 12:357-63.
- [5] M. Rajkumar, C.R. Harish, K. Asres, C. Veeresham (2008). *Toddalia asiatica* (Linn) Lam-A comprehensive review. *Pharmacogn Rev*; 2:386-97.
- [6] K. Maiza, R. A. Brac de la Perrière, V. Hammiche Pharmacopée traditionnelle saharienne : Sahara septentrional. *In: Schröder, E., Balansard, G., Cabalion, P., Fleurentin, J., Mazars, G. (1993). Médicaments et aliments : L'approche ethnopharmacologique. Actes du 2ème Colloque Européen d'Ethnopharmacologie et de la 11<sup>ème</sup> Conférence internationale d'Ethnomédecine. Heidelberg, pp. 169-171.*
- [7] P.H. Julve (2015). ff- Baseflor. Index botanique, écologique et chorologique de la flore de France.
- [8] A.L. Tadjeddine, N. Kambouche, H. Medjdoub, B. Meddah, A. Dicko *et al.*, (2013). Antidiabetic effect of *Anacyclus valentines* L. aqueous extract in normoglycemic and streptozotocin induced-diabetic rats. *American Journal of Phytomedicine and Clinical Therapeutics*. *AJPCT* 5 424-43.
- [9] I. Hacheimi and O. Kadi (2009). Effet de l'extrait aqueux de *L'Anacyclus Valentinus* l sur le cholestérol.
- [10] C. Selles, M.A. Dib, N. Djabou, F. Beddou, A. Muselli, B. Tabti, J. Costa and B. Hammouti (2013). Antimicrobial activity and evolution of the composition of essential oil from Algerian *Anacyclus pyrethrum* L. through the vegetative cycle, *Natural Product Research*, 11:46.
- [11] K. Boungab, A. Tadjeddine, L. Belabid, Z. Fortas, F. Lazrag (2011) Antifungal activity of extracts of *Anacyclus valentinus* L. on phytopathogenic fungi. 4th International Conference on Alternative Methods in Crop Protection. Evolution of French and European regulatory frameworks. Innovative new means and strategies, New Century, Lille, France. 230- 238.
- [12] G. Harald (1978). Comparative phytochemistry and systematics of *Anacyclus*. *Biochemical Systematics and Ecology*, 1978; 6: 11–17.
- [13] Sawsan Abuhamdah, Rushdie Abuhamdah, Suleiman Al-Olimat and Paul Chazot (2013). Phytochemical Investigations and Antibacterial Activity of Selected

- Medicinal Plants from Jordan. *European Journal of Medicinal Plants* 3(3): 394-404.
- [14] N. Boizot and J-P. Charpentier (2006). Méthode rapide d'évaluation du contenu en composés phénoliques des organes d'un arbre forestier. Cah. Tech. INRA. N°. special. pp. 79-82.
- [15] V. Dewanto, X. Wu, K.K. Adom, R.H. Liu (2002). Thermal Processing Enhances the nutritional Value of Tomatoes by increasing total antioxidant activity. *J. Agric. Food Chem.* 50 : 3010–3014.
- [16] H. Khan, M. Saeed, A.U.H. Gilani, M.A. Khan, A. Dar, I. Khan (2010). The antinociceptive activity of *Polygonatum verticillatum* rhizomes in pain models. *J Ethnopharmacol*, 127(2):521–527.
- [17] E. Woode, E. Boakye-Gyasi, C.A. Danquah, C. Ansah, M. Duwiewua (2009). Anti-arthritis effects of *Palisota hirsuta* K. Schum. Leaf extract in Freund's adjuvant arthritis in rats. *International journal of pharmacology*. 5 (3): 181-190.
- [18] Abdel-Moein N.M., Abdel-Moniem E.A., Mohamed D.A. and Hanfy E.A. (2011). Evaluation of the anti-inflammatory and anti-arthritis effects of some plant extracts. *grasas y aceites*, 62 (4). 365-374.
- [19] H. Gerhard Vogel (2002). Drug discovery and evaluation, pharmacological assays, Second edition, p 802- 803.
- [20] L.L. Zhang, W. Wei, S.X. Yan, X.Y. Hu, W.Y. Sun (2004). Therapeutic effects of glucosides of *Cheanomeles speciosa* on collagen-induced arthritis in mice. *Acta Pharmacologica Sinica* 2004; 25: 1495–1501.
- [21] P.D. Eckersall & A.S. Nash (1983). Isoenzymes of canine plasma alkaline phosphatase : an investigation using isoelectric focusing and related to diagnosis, *Res. Vet. Sci.*, 1983, 34, 310-314.
- [22] Karnati Mamatha, Chandra Rodda H., Veeresham Ciddi, Kishan Bookya (2013). Anti -arthritis activity of root bark of *Oroxylum indicum* (L.) vent against adjuvant-induced arthritis. *Pharmacognosy Research* ; Vol 5 (2) : 121 – 128 .
- [23] S.R. Yend, V.D. Sannapuri, N.S. Vyawahare, U.N. Harle (2010). Antirheumatoid activity of aqueous extract of *Piper nigrum* on Freund's Adjuvant induced arthritis in rats. *Int J Pharma Sci Res.* 1(1): 129-33.
- [24] A.D.Kshirsagar, P.V. Panchal, U.N. Harle, R.K. Nanda, H.M. Shaikh (2014). Antiinflammatory and antiarthritic activity of anthraquinone derivatives in rodents. *Int. J. Inflamm.* 12690596.
- [25] R. Roubenoff, R.A. Roubenoff, J.G. J.J. Cannon, Kehayias, B. Zhuang, B. Dawson-Hughes, *et al.* (1994). Rheumatoid cachexia: cytokine driven hypermetabolism accompanying reduced body cell mass in chronic inflammation. *J Clin Invest*; 93:2379–86.
- [26] E. Brunet-Guedj, B. Brunet, J. Girardier, B. Moyon (2006). *Medecine du sport*. 7th ed. Masson. pp. 263–7.
- [27] A.C. Issekutz, K. Sapru (2008). Modulation of adjuvant arthritis in the rat by 2 methoxyestradiol: an effect independent of an anti-angiogenic action. *Int. Immunopharmacol.* 8, 708–716.
- [28] C. Gebhard, S.F. Stämpfli, C.E. Gebhard *et al.* (2009). Guggulsterone, an anti-inflammatory phytoesterol, inhibits tissue factor and arterial thrombosis. *Basic Res Cardiol*;104 (3):285-94.
- [29] D. Ricklin, G. Hajishengallis, *et al.* (2010). "Complement: a key system for immune surveillance and homeostasis." *Nat Immunol* 11(9): 785-797.
- [30] A. Akhtar, Deshmukh A.A., Raut C.G., Somkuwar A.P., & Bhagat S.S. (2012). Prallethrin induced serum biochemical changes in Wistar rats. *Pesticide Biochemistry and Physiology*, 102: 160-168.
- [31] S. Dubucquoi & S.Fily-Nalewajk (2008). Prise en charge de la polyarthrite rhumatoïde en 2008 : la biologie peut-elle répondre aux attentes des cliniciens ? *Rev Fr Laboratoires* ;404:51-7.
- [32] M.B. Pepys, G.M. Hirschfield (2003). C-reactive protein: a critical update, *Journal of Clinical Investigation* 111:1805–1812.
- [33] E.D. Harris (1990). Rheumatoid arthritis. Pathophysiology and implications for therapy. *N Eng J Med*.322(18): 1277-89
- [34] K. Batanouny (2005). Guide to Medicinal Plants in North Africa. Centre for Mediterranean Cooperation. *International Union for Conservation of Nature and Natural Resources*, 1: 35-37.
- [35] G. Benitez, M.R. Gonzalez-Tejero and J. Molero-Mesa (2010). Pharmaceutical ethnobotany in the western part of Granada province (southern Spain): Ethnopharmacological synthesis. *J. Ethnopharm.*, 129: 87–105.
- [36] Y.K. Kim, Y.S. Kim, S.U. Choi, S.Y. Ryu (2004). Isolation of flavonol rhamnosides from *Loranthus tanakae* and cytotoxic effect of them on human tumor cell lines. *Arch. Pharm. Res.* 27:44 - 47.
- [37] Bahmani Mahmoud, Shirzad Hedayatollah, Majlesi Maedeh *et al.* (2014). A review study on analgesic applications of Iranian medicinal plants. *Asian Pac J Trop Med*; 7(Suppl 1): S43-S53.
- [38] G. Odontuya, J. R. S. Hoult, and P. J. Houghton (2005). Structure-activity relationship for anti-inflammatory effect of luteolin and its derived glycosides. *Phytother. Res.* 19: 782 - 786.