

Study on Toxic Impact of Sugar Factory Effluent on the Gill of the Fresh Water Fish *Rasbora Daniconius*

V. B. Kakade

Dept.of Zoology, E.S.Divekar College Varvand, Tal. –Daund, Dist.Pune. 412 215 M.S., India.

Abstract— The fresh water fish *Rasbora daniconius* were exposed to two sublethal concentration of sugar factory effluent for 4 weeks studied. The concentration were record 1/5(2.2%) and 1/10(1.1%) of the 96 hrs LC₅₀ values of sugar factory effluent. The gills of *R. daniconius* showed the curling and degeneration and breaking of epithelium cells of the secondary gill lamellae, destruction of blood cells, blood capillaries and nuclei were the prominent features of the gill.

Keywords— *R. daniconius*, Sugar factory effluent, Histopathological changes and tissues of gill.

I. INTRODUCTION

Fishes have most widely been used as a test organism to evaluate the toxicity of west and other pollutants may be due their adaptability to laboratory condition, availability and varying degree of sensitivity to toxic substances.

In the present study an attempt has been to determine pathological changes induced by sugar factory effluent.

Histologically, gills have a large superficial area through which gaseous exchanges between the blood and the external medium take place (Newstead, 1987). The direct contact between gills and water promotes the interaction with toxic substances present in the water as they have sites of ionic link of performing normal functions. Adsorption of metal and other pollutant with charges may eventually bring about toxic effect on the organism (Hollis and Playle, 1997). The thin lamellae that cover the secondary lamellae represent the largest site for gaseous exchanges. The chloride cells, responsible for ionic exchanges, are usually distributed among the secondary lamellae under condition of low ionic concentrations, besides transporting Na⁺, Cl⁻ and other substances.

Many workers have studied histopathology of tissues after exposing fishes to different pesticides or heavy metals or industrial effluent. Mitrovic and Brown (1968) reported

congestion in blood vessels and changes in gills due to heavy metal poisoning.

Srivastava (1984) studied the histopathology of gills of *Channa gachua* after exposure to sublethal concentrations of Malathion and Chloradene. Kulshrestha *et al.*, (1984) studied histopathological changes due to exposure to pesticides in *Channa striatus*. Singh and Sahai (1984) recorded gill damage in *Rasbora daniconius* exposed to BHC. Histopathological changes in gill, kidney, liver and intestine of *Garra mullya* due to mercury exposure have been studied by Gokhale (1984).

The review of the literature shows the effects of effluent bring alterations in the structure of important body tissues of gill. The present investigation was undertaken to explore, observe, and record the changes in different tissues of *Rasbora daniconius*.

II. MATERIALS AND METHODS

The fresh water fish, *Rasbora daniconius* were brought from river Bhima near Kangaon, Tal. Daund, Dist. Pune and acclimatized to laboratory conditions for about two weeks. The healthy fishes of uniform length and weight were selected and were exposed to two sub lethal concentrations of sugar factory effluent. The sublethal concentrations were selected on basis of the results of acute toxicity vaules. The LC₅₀ value for 96 hours was estimated at 11%. The Sublethal concentrations for chronic test were selected at 2.2% (1/5) and 1.1% (1/10).

The food was supplied every alternate day and weekly observations were made, where as water was renewed every week during the exposure period. The aquaria were, kept away from mechanical disturbances.

At the end of exposure, survived fishes were taken out from aquaria and decapitated; tissues of Gill were fixed in Bouin's fluid, processed and embedded in paraffin wax. Section at 4-6 μ thickness were cut and stained in Harris

haematoxylin and eosin as suggested by Bancroft and Stevens (1977) and Bancroft and Cook (1984). After the staining the slides were mounted in DPX and observed under the light microscope for histological details and subsequently photomicrographs were taken.

III. RESULTS

NORMAL HISTOLOGY

1. Gill (Photographs No. 1)

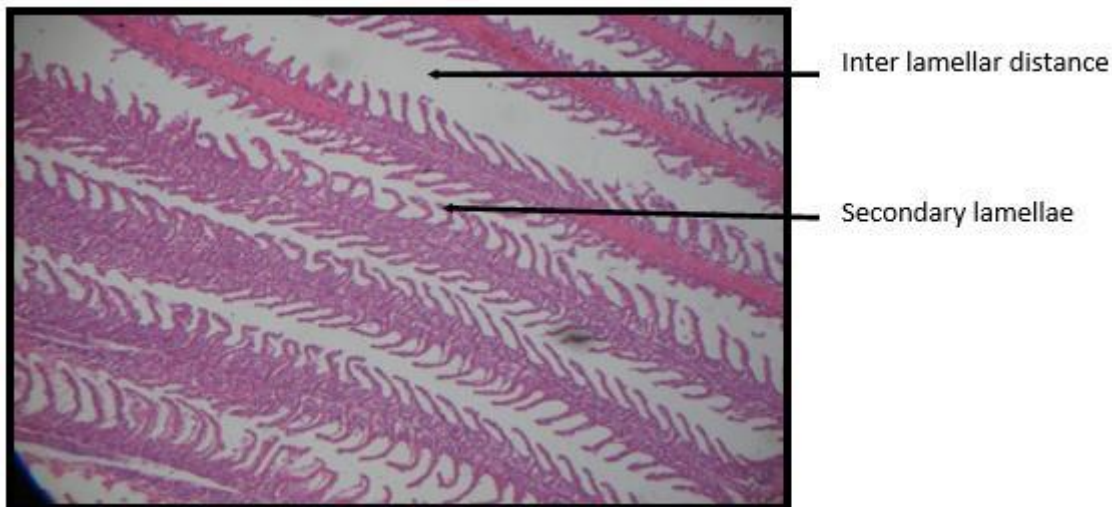
Rasbora daniconius possesses four pairs of gills situated at branchial chamber, as in other teleosts. Each gill arch, has a double row of elongated, laterally projecting structures, the primary gill filaments. On the upper and lower surface, leaf like projection at right angle to its axes is the secondary gill

lamellae. A delicate flattened structure comprising of two epithelial sheets are continuous to its free end secreted along its length as large number of widely separated pillar cells there is the continuous blood space between two pillar cells. The pillar cells are arranged in rows occupying the whole area of secondary gill lamellae.

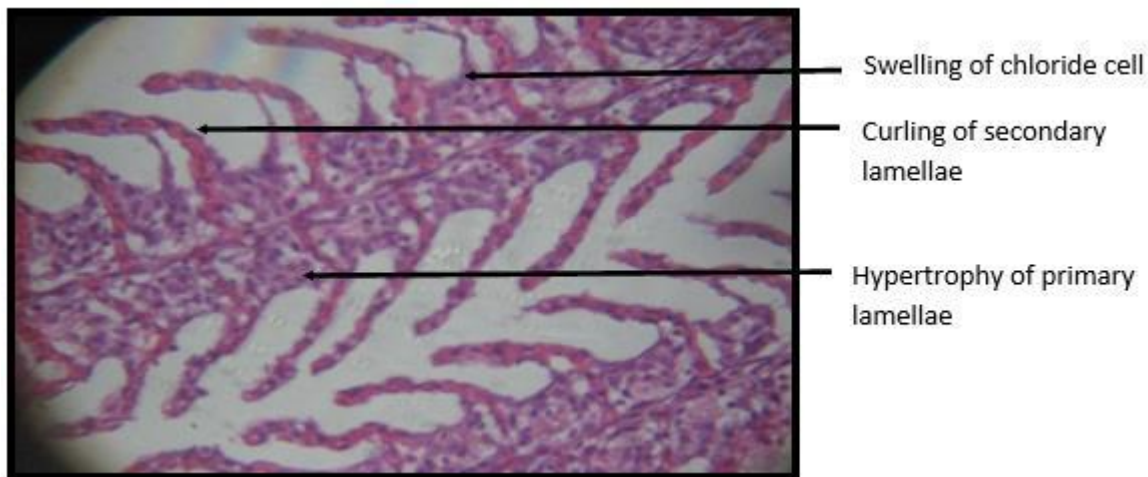
HISTOPATHOLOGICAL CHANGES

2. Gill: - (Photograph No.2&3)

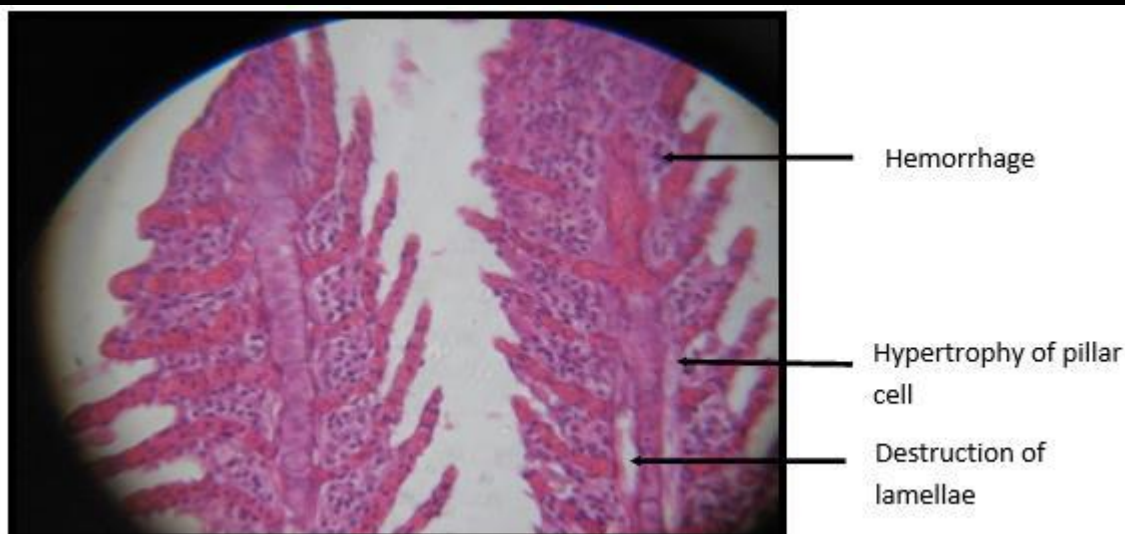
The gill of *R. daniconius* exposed to sub lethal concentrations of sugar factory effluent showed curling, the degeneration and breaking of epithelium cells of the secondary gill lamellae, hypertrophy, destruction of blood cells, blood capillaries and nuclei were the prominent features of the gill.



Photograph No.1: L.S. of gill of *R. daniconius* (Control). Hematoxyline /Eosin



Photograph No.2: L.S. of gill of *R. daniconius* after 1.1 % conc. (Chronic) exposed to sugar factory effluent Hematoxyline/ Eosin



Photograph No.3: L.S. of gill of *R. daniconius* after 2.2% conc. (Chronic) exposed to sugar industry effluent. Hematoxyline/Eosin

IV. DISCUSSION

Study of the literature on fish histopathology reveals that many workers contributed on different aspects of fish tissues. Carpenter *et al.*, (1927) found fish dead due to coagulation of mucous over gills which impaired respiration. The trouts exposed to sulphonate detergent were found with damaged gill (Schimid and Mann, 1961) and sulphonate detergent effect was recordable on the gills of *Lepomis gibbosus* exposed to acute and chronic bioassays (Cairns and Scheiner, 1964) sulphonate effect was recorded on the blue gill, *L. macrochirus* by Lamke and Mount, 1963) Brown *et al.*, 1968 studied the damage of gills by detergent done and by natural detergent and Zinc.

The histopathological changes in heart, liver and gills exposed to sub lethal concentration of sodium arsenate were studied by Giderenus (1966). Khangarot and Somani (1980) studied the mercury toxicity on *Puntius sophore* and reported that the gill epithelium is separated from the basement membrane and pillar cells. Haniffa and Sundaravadhanam (1984) observed partial destruction of gill epithelium, pillar cells, acidophil, mast cells, blood cells, blood capillaries, cartilage cells, separation of epithelial layer of secondary lamellae from basement membrane, mucous cells destroyed and gill filaments were seen completely covered by thick mucous layer on distillery effluent treated *Barbus stigma*.

Paulose (1989) reported fusion of adjacent lamellae in the gill of *Labeo rohita* within 15 days of exposure either to Methyl mercury or mercuric chloride 65.

Nath and Kumar (1989) reported changes in gills of *Colisa fasciatus* exposed to sublethal concentration (64 ppm) of

Nickel Sulphate, like hypertrophy of respiratory and mucous cell, separation of epithelial layer from pillar cell system, extensive necrosis and hyperplasia layer from pillar cell system, extensive necrosis and hyperplasia leading to clubbing at the tip of lamellae.

Moza *et al.*, (1993) reported pathological changes in gills of *Carassius auratus*, induced by Cadmium and found epithelial lifting hyperplasia, lamellar fusion, vacuole formation in pillar cells was observed on 10th day of exposure; more prominent hyperplasia, congestion of blood stasis, necrotic epithelia cells, depletion of cells in between inter-lamellar zone i.e. complete cell necrosis and vacuole formation in pillar cells was observed on 20th day of exposure. Saksena and Pandey (1993) reported the hyperplasia, hypertrophy, fusion of secondary gill lamellae, desquamation of epithelium, increased number of mucous cells in the gill of Copper Sulphate exposed *Labeo rohita*.

Ashok and Vinod (1995) studied changes in gill surface of *R. daniconius* exposed to sub lethal concentration of 0.05 mg/l of Mercury ($HgCl_2$) 96h and found damage, fusion and dumping in the swollen, deterioration and modification of ring ridges into more expanded surface area in the secondary lamellae.

Adsorption of metal and other pollutant with charges may eventually occur bring about toxic effect on the organism (Hollis and Playle, 1997). The thin lamellae that cover the secondary lamellae represent the largest site for gaseous exchanges. The chloride cells, responsible for ionic exchanges, are usually distributed among the secondary lamellae under condition of low ionic concentrations, besides transporting Na^+ , Cl^+ and other substances.

Erkman *et al.*, (2000) studied histopathological changes induced by cyphenothrin in gill of *Lebistes reticulatus* and found lifting of the epithelial layer from gill lamellae, degeneration of secondary lamellae due to edema, shortening of secondary lamellae and club shaped lamellae.

Prasad (2002) studied the effect of Copper and Zinc on the gill of *Channa marulius* and found necrosis, exudation of erythrocytes from the secondary lamellae, vacuolization and separation of basement membrane from the epithelial cells curling and fusion of some secondary lamellae after 2160 hours exposure. Thophon *et al.*, (2003) noticed aneurism with rupture of respiratory epithelium of secondary lamellae and breakdown of pillar cell system in the gills in Cadmium exposed *Lates calcarifer*.

Vutukuru *et al.*, (2005) observed architecture changes in the gill morphology like loss, fusion, clubbing of secondary lamellae and detachment of gill racker following softening of gill shaft in Copper treated fish, *Esomus danicus*.

Olojo, (2005) was observed fingerlings of the fish *Clarias gariepinus* were exposed to continuous exposure to sub lethal concentrations (0.006mg/l and 0.008mg/l) of lead for three weeks, showed distortion of gills, the swimming became slower and there was reduction in their rate of feeding primary and secondary lamella overlapping occlusion of inter lamella spaces, epithelium is completely disrupted owing to the lyses of the cells. The increase intracellular vaculation signals onset of edematous changes.

Soni and Gupta (2006) studied histopathological changes due to mercuric chloride and influence of EDTA on the gill of *Heteropneustes fossilis* and recorded histopathological changes in the gill due to long term exposure of the fish to mercuric chloride, are severe. Oedematous condition and vacuolization in the cells of gill rays, hypertrophy in gill septum, breakage in the epithelium covering enlarged micropillaries and small separated pillar cells have been clearly observed. Altinok and Capkin (2007) observed lesions in the gill of rainbow trout exposed to 0.6 or 1.3 mg/l endosulfan concentration consisted oedema, separation of epithelium from lamellae, lamellar fusion and swelling of the epithelial cells. Suchithra *et al.*, (2007) noticed bulging of the hyperemic secondary lamellae in to the lumen of the accessory respiratory organ, necrosis and swelling of the respiratory epithelium leading to hemorrhages and fusion of secondary lamellae of cadmium chloride exposed fish, *Heteropneustes fossilis*.

Aniladevi *et al.*, (2008) reported that, after 21 days of pesticides exposure gill become edematous with prominent clubbing. Separation of primary gill lamellae and hemorrhage in the vessels outside the secondary gill

lamellae were observed. Hadi and Alwan (2012) studied the histopathological changes in gill of fresh water fish, *Tilapia zilli*, exposed to aluminum shows that the cellular hypertrophy in the epithelial layer of primary filaments and fusion of secondary lamellae, epithelial lifting, interstitial edema and blood congestion in axis of the primary filament, necrosis of gill epithelium tissue.

The present study reveal extensive damage to the inter gill architecture on fish have been noticed compared to control fish. Changes like bulging at tip of primary lamellae, epithelia hypertrophy. Fusion, curling and reduction of secondary gill lamellae, disorganization and rupture in secondary lamellae, swelling in pillar, mucous, and chloride cells and their nuclei appear swollen and pyknotic. Hemorrhage at primary and secondary lamellae in the sugar factory effluent treated fish in contract to control fish. The pathological changes in the gills might have resulted due to shifting from aerobic to anaerobic pathway in tissues respiration of fish. Histological evidences in the present study are correlated to some extent with the work of Sonawane and Khillare (1992), Singh and Karpagaganapathy (1988), Usha Rani (1999), Suchithra *et al.*, (2007) Aniladevi *et al.*, (2008).

REFERENCES

- [1] Altinok, I. and Capkin, E. (2007): Histopathology of rainbow trout exposed to sublethal concentrations of methiocarb of endosulfan. *Toxicologic Pathology*. 35: 405-410.
- [2] Aniladevi, K.K.P., Philip, B., Bhanu, S.V. and Jose, J. (2008): Histopathological effects on *Oreochromis mossambicus* (Tilapia) exposed to chlorpyrifos. *J. Environ. Resh and Develop*. Vol (2): 553-559.
- [3] Ashok Kumar and Vinod Kumar, (1995), Mercury poisoning : architectural changes in the gills of *Rasbora daniconius* (Hamilton). *J. Environ. Biol*. 16(1) : 33-36.
- [4] Bancroft, J.D. and H. C. Cook (1984): Manual of histology techniques, (Ed) Livingstone, C., London. 6- 28.
- [5] Bancroft, J.D. and A. Stevens (1977): Theory and practice of histological techniques, (Ed) , Livingstone, C., Novea publication, London.
- [6] Cairns, J. and Scheier, A. (1964): The effect upon the pumpkin seed sun fish *Lepomis gibbosus* (Linn) of chronic exposure to lethal and sublethal concentrations of dieldrin. *Natur. Nat*. 370 : 10.

- [7] Carpenter, K. E. (1927): The lethal action of soluble metabolic salts of tissues. *Brit. J. Expt. Biol.*, 4 : 378-390.
- [8] Erkman, B., Caliskan, M. and Yerli, S.V. (2000): Histopathological effects of cyphenothrin on gill of the *Lebistes reticulatus*. *Vet Hum. Toxicol.* 42: 5-7.
- [9] Giderenus, P. A., (1966): Some effect of sublethal concentrations of sodium arsenate on blue gill and aquatic Environment. *Trans. Am. Fish. Soc.*, 95 : 289-296.
- [10] Gokhale, M. A. and wagh (1984): Effect of mercury toxicity to *Garra mullya* (Sykes). M.Phil. dissertation, Pune University, Pune, India.
- [11] Haniffa M.A. and Sundaravathanam, S. (1984): Effect of distillery effluent on food utilization of freshwater fish *Barbus Stigma*, *Life Sci. Adv.*, 2.143-146.
- [12] Hadi A. A. and Alwan S. F. (2012) Histopathological changes in gill, liver and kidney of the fresh water fish *Tilapia zilli* exposed to aluminium, *International Journal of Pharmacy and Life sciences(IJPLS)*, Vol.3(11), 2071-2081.
- [13] Hollis, L. and Playle, R.C. (1997): Influences of dissolved organic matter on copper binding and calcium on cadmium binding by gill of rainbow trout. *J. of Fish Biology.* 50, 703-720.
- [14] Khangarot, B. S. and Somani, R. C. (1980): Toxic effect of mercury on the gill of freshwater teleost, *Puntius sophore* (Hamilton). *Current Science.* 49 (21): 832-83
- [15] Khillare, Y.K. and Davane, P.M. (1998): Chronic effect of water variable on development gill and supporting cells in early life stage of fish, *Puntius stigma*. *J. Environ. Biol.* 19(2): 125-129.
- [16] Kulshreshta, S. K., Shrivastava, R. S. and Arora, N., (1984): Toxicity of two pesticides to the kidney of a freshwater teleost *Channa striatus* (Bloch.) *Ibid* : 63-70.
- [17] Mitrovic, V.V., Brown, V.M., Shutben, D.G., and Berryman, M.H., (1968): Some pathological effects of subacute and acute poisoning of rainbow trout by phenol in hard water. *Water Res.* 2 : 249-254.
- [18] Moza, U., Glazerbook, J. and Mitchell, B.M. (1993): Pathological response of gold fish, *Carassius auratus* (L.) to cadmium at sublethal level. *Third Ind. Fish. Forum. Proceeding, Pantnagar.* 11-14 Oct. pp. 181-189.
- [19] Nath, K. and Kumar, N. (1989): Nickel induced histopathological alteration in the gill architecture of a tropical freshwater perch, *Colisa fasciatus* (Bloch and Schn). *Sci. Total Environ.* 80: (2/3): 293-296.
- [20] Newstead, J.D. (1987): Fine structure of the respiratory lamellae of teleostean gill. *Zeitschrift fur Zellforschung.* 70,420-445.
- [21] Olojo, E.A.A., Oluzin K.B., Mbaka G. and Oluwem (2005): Histopathology of gill and liver tissues of the catfish *Clarias gariepinus* exposed to lead. *African Journal of Biotechnology* Vol. 4 (1). Pp. 117-122. January 2005.
- [22] Paulose, P.V. (1989): Histopathological changes in relation to accumulation and elimination of inorganic and methyl mercury in gill of *Labeo rohita*. *Indian. J. Exp. Biol.*, 27: 2185-2196.
- [23] Prasad, B.B. (2002): Effect of copper and zinc in the gills of *Channa marulius*. *J. Ecotoxicol. Environ. Monit.* 12(1):35-40.
- [24] Saksena, D.N. and Pandey, R. (1993): Copper sulphate induced histopathological alterations in the gill of the fingerlings of an Indian major carp, *Labeo rohita* (Ham.). *J. NATCON.* 5-1- (65-69).
- [25] Schimid, O. J., and Mann, H., (1961): Action of detergent (detecy benzene, sulphonate) on gills of trout. *Nature* (London), 92-675
- [26] Singh, S.B. and Kaepagagnapthy, P. R. (1988): Effect of dimethoate on histology of the gill in the freshwater fish, *Barbus stigma*. *Proc. Of the Second. Nat. Symp. On. Ecotoxicol.* 146-148.
- [27] Singh, S. and Sahai, S., (1984): Histopathological changes in the gills of *Rasbora daiconius* induced by BHC. *J. Environ. ,Bio.*, 5 : 65-67.
- [28] Sonawane, D.L. and Khillare Y.K.(1992): Toxicosis of the industrial effluent in freshwater fishes from Marathwada region. *Ph.D. Thesis Marathwada University, Aurangabad* (MH.) India.
- [29] Soni, S and Gupta, U.S. (2006 b): Toxic effect of mercuric chloride and influence of EDTA on the gill of *Heteropneustes fossilis*. (Bloch). *Proc. Zool. Soc. India.* 5 (1): 47-59.
- [30] Srivastava, J. and Srivastulla, A. K. (1984): Histopathology of the gills of *Channa gachua* exposed to sublethal concentrations of malathion and chlordane. *Proc. Sem. Eff. Pest. Aq. Fau.* 37-44.
- [31] Suchitra, N., Jothivel, N., Jayakumar, P. and Paul, V.I. (2007): Toxicological impact of cadmium chloride on the air breathing catfish *Heteropneustes fossilis*. *Iran J. Environ. Health. Sci. Eng.* Vol.4. No.1, 9.8.

- [32] Thophon, S., Kruatrachue, M., Upatham, E.M., Pokethitiyook, P., Sahaphong, S., Jaritkhuan, S. (2003): Histopathological alteration of white seabass, *Lates calcarifer* in acute and subchronic cadmium exposure. *Environ. Pollut.* 21: 307-320.
- [33] Usha Rani, A. (1999): Pathological observation in gill of the freshwater teleost, *Oreochromis mossabicus* (Tilapia) with reference to cadmium toxicity. *Indian journal of Comparative Animal physiology.* Vol. 17.1, 18-22.
- [34] Vutukuru, S.S., Ch.Suma, K. Radha Madhavi, Juveria, J. Smitha Pauleena, J. Venkateswara rao and Y. Anjaneyulue (2005): Studies on the development potential biomarkers for rapid assessment of copper toxicity to freshwater fish using *Esomus darricus* as model. *Int. J. Environ. Res. Public Health.* 2(1): 63-67.