



Effect of stinging nettle extract and potassium bromate on histological and physiological changes of male rabbit reproductive organs

F. Abuajaila Sabriyah and M. Aboubakr Salma

Zoology Department, Faculty of Science, Al-Qubba, Derna University, Libya

Corresponding author: sabriyahabuajaila@gmail.com

Received: 07 Jan 2025; Received in revised form: 10 Feb 2025; Accepted: 19 Feb 2025; Available online: 23 Feb 2025

©2025 The Author(s). Published by Infogain Publication. This is an open-access article under the CC BY license

(<https://creativecommons.org/licenses/by/4.0/>).

Abstract— This study was conducted to evaluate the various effects of nettle extract and potassium bromate on the histological and physiological changes of male rabbit reproductive organs and semen quality. Rabbit breeding experiments were conducted on a private farm in Lamluda region, Al-Qubba city, eastern Libya, during the year 2024. Rabbits were divided into three groups: the first was dosed with potassium bromate, the second was dosed with nettle extract, and the third was dosed with potassium bromate for three days followed by nettle extract for three days, compared to the fourth group, as a control group. At the experiment's end, all animals were sacrificed, their epididymides were removed, and sperm assays were performed. The results showed that the weights of rabbits treated with potassium bromate and a mixture of potassium bromate + nettle extract decreased by 26.59% and 19.48% compared to the control, and the testis weight decreased by 190.39%, 25.83%, and 71.59% for each of the samples treated with potassium bromate, nettle extract, and the mixture of both compared to the control, respectively. The findings revealed that animals exposed to potassium bromate had a significantly decreased sperm count, higher semen viscosity, distracted and erratic sperm motility, and abnormalities in the sperm, with the head becoming spherical and the tail short, broken, and divided. The use of nettle extract, however, reduced these disturbances.



Keywords— *Urtica dioica*, stinging nettle, potassium bromate, reproductive organs, semen quality

I. INTRODUCTION

According to Thomford *et al.* (2015), the use of medicinal plants for therapeutic purposes has traditionally earned widespread acceptability for health care in local communities around the world, owing to cheap or no cost, poverty, scarcity, or a lack of access to modern pharmaceuticals. Extracts from medicinal plants and their bioactive metabolites have proven to be effective in the treatment and prevention of many diseases. Stinging nettle, or *Urtica dioica*, is an important medicinal herb from the *Urticaceae* family. Nettle is an herbaceous perennial-blooming herb that has long been renowned for its therapeutic value in folk medicine (Awoyemi *et al.*, 2022). Where Edirne *et al.* (2010) reported that the various phytochemicals found in the leaves and roots of *Urtica*

dioica (Nettle) extract could be used for many therapeutic purposes, such as treating infertility.

Urtica dioica L. (stinging nettle) is a perennial herb that grows in temperate and tropical areas including northern Africa, Europe, Asia, and North America. It has long been used as a traditional herbal medicine for several illnesses, and as a nutritional supplement. The plant's aerial parts are also used in traditional medicine (Albadawi *et al.*, 2024). With the leaf appearing in numerous cultures for a varied variety of ailments, including diabetes, asthma, and hypertension (Mohamed *et al.*, 2024)

Chemically, stinging nettle is a complex mixture of water and alcohol-soluble compounds, including phenolic, sterols acids, proanthocyanidins, coumarins,

lectins, flavonoids and their glycosides, fatty acids, vitamins, polysaccharides, carotenoids, and minerals. The leaves contain amino acids, flavonoids, carotenoids, phenolic acids, and fatty acids. Nettle-derived compounds such as rutin, kaempferol, and vitamin A have been demonstrated to have anti-inflammatory, antioxidant, immunomodulatory, and anticancer properties (Albadawi *et al.*, 2024; Devkota *et al.*, 2022). *Urtica dioica* leaf extract with high quantities of quercetin, esculetin, scopoletin, and rutin showed anti-inflammatory and antioxidant activity in diabetic mouse hippocampal neurons (Albadawi *et al.*, 2024; Patel *et al.*, 2018). It includes several beneficial compounds for human health, such as polyphenols, triterpenoids, sterols, flavonoids, lectins, and fatty acids. Clinically important mechanisms include antioxidant and anti-inflammatory effects, suppression of 5 α -reductase and aromatase, and antiproliferative and cell cycle arrest in malignancies. Preclinical studies have demonstrated benefits in both benign prostate hyperplasia or hypertrophy (BPH) and prostate cancer cell lines, as well as the prevention of diabetes-induced reproductive dysfunction (Leisegang, 2021). This plant has also been reported to have anticancer (Durak *et al.*, 2004), anti-inflammatory (Hajhashemi, and Klooshani, 2013), anti-osteoporotic (Gupta *et al.*, 2014), antihypertensive, hypoglycemic, hepatoprotective (Roschek *et al.*, 2009), testicular protective effects, and the ability to improve the quality of spermatozoa and sperm parameters (Jalili *et al.*, 2014).

Potassium bromate is a colorless, odorless white crystal or powder, highly soluble in water and less soluble in acetone, dimethyl sulfoxide, ethanol, methanol, and toluene (National Toxicology Program, 1992) (Thompson 1992). In distilled water, potassium bromate degrades to form potassium bromide (KBr) and oxygen (O₂). However, under the optimum conditions, it is converted to potassium bromide, which is not harmful for consumption. Potassium bromate is an oxidizing agent that is used throughout the baking process for fermentation and proofing. As a result, potassium bromate is a popular food additive in bread to improve its baking effect, as well as in textile dyeing and as a neutralizer in the cosmetic industry. However, numerous reports have documented its harmful impact on human health. The IARC considers it a probable human carcinogen and classifies it as 2B (Shanmugavel *et al.*, 2020; Sahu *et al.*, 2016). It has also been reported to cause some acute health consequences, such as abdominal pain, diarrhea, and irritation to the mucous membrane of the upper aero digestive tract, and vomiting (Nkwatoh *et al.*, 2023; Adebisi *et al.*, 2022). As a result, many governments around the world have partially or entirely outlawed it.

The purpose of this study is to assess the varied impacts of stinging nettle extract on the histological and physiological changes of male rabbit reproductive organs treated with potassium bromate.

II. METHODOLOGY

2.1. Preparation of leaves extract of Nettle

Nettle leaves were collected and washed with distilled water, after that were dried in the oven. The dried leaves were blended to powder using a kitchen blender. 10 g of the powdered leaves was soaked in 100 ml distilled water with intermittent shaking as a cold maceration extraction. The root extract was concentrated using a rotary evaporator and further using a water-bath. The resulting solution was filtered to obtain the pure extract, which was then distributed into 10 ml test tubes and centrifuged at 3500 rpm for 20 minutes. The filtered extract was collected and condensed with a rotary evaporator to get the dry extract. Next, refrigerate the extract until needed, then dilute it with 1 mL of distilled water for each dosage.

2.2. Preparation of potassium bromate

Potassium bromate (KBrO₃) was prepared with a concentration of 1% by dissolving 1 g of potassium bromate powder in 100 ml of distilled water in a glass flask.

2.3. Animal experimental model

16 male rabbits with an average of 845 g (829-890g) were picked from the animal home. The rabbits were grouped into 4 treatment groups; each group consisted of 4 rabbits (4 rabbits per cage). Cages were kept in a well-ventilated room with typical circumstances (25 \pm 2°C, 55-60% RH, 12:12 h light/dark cycle).

- ❖ Group I: (Control): Without any treatments (as control).
- ❖ Group II: This group's rabbits were given 2 ml potassium bromate each for 3 days.
- ❖ Group III: This group's rabbits were given 2 ml *Urtica dioica* extract each for a week.
- ❖ Group IV: This group's rabbits were given 2 ml of potassium bromate each for three days, and on the fourth day, they were followed by 2 ml of nettle extract each for a week.

2.4. Characteristics studied

At the end of the experimental period after 10 days, the following characteristics were studied on all rabbits in the experiment:

- ❖ Rabbits weight (g).
- ❖ Testis weight (mg).

- ❖ Semen quality: Sperm analysis which contain (sperm motility, sperm concentration, sperm counts, sperm morphology, and semen viscosity), were determined according to WHO protocol 2010.
- ❖ Testosterone concentration in blood (ng/ml).

2.5. Statistical analysis

One-way analysis of variance (ANOVA) was used with SPSS to evaluate differences between groups. The least significant difference (LSD) test was used as a post hoc test for intergroup comparisons, and p value <0.05 was considered statistically significant.

III. RESULTS AND DISCUSSION

The data in the following graphs (1, 2) illustrate the effect of dosing male rabbits with potassium bromate

and nettle extract on the weight of rabbits and testicle weight. The results show that using potassium bromate alone or with nettle extract reduced the weight of male rabbits by 26.95% and 19.18%, respectively. On the contrary, treating male rabbits with nettle extract increased the weight of rabbits at the end of the experiment by 23.61% (fig.1). On the other hand the testicle weight decreased by 190.39%, 25.83%, and 71.59% for each of the samples treated with potassium bromate, nettle extract, and the mixture of both compared to the control, respectively (fig.2). This results agree with **Elsheikh *et al.*** (2016), where reported the usage of potassium bromate in water led to reduce weight of testicle in rates. Similarly, many researchers found that endocrine disrupting chemicals reduce pubertal body weight. Factors known to alter thyroid function are also accused of limiting physiologically active iodine (**Klinefelter *et al.*, 2004; Elsheikh *et al.*, 2016**).

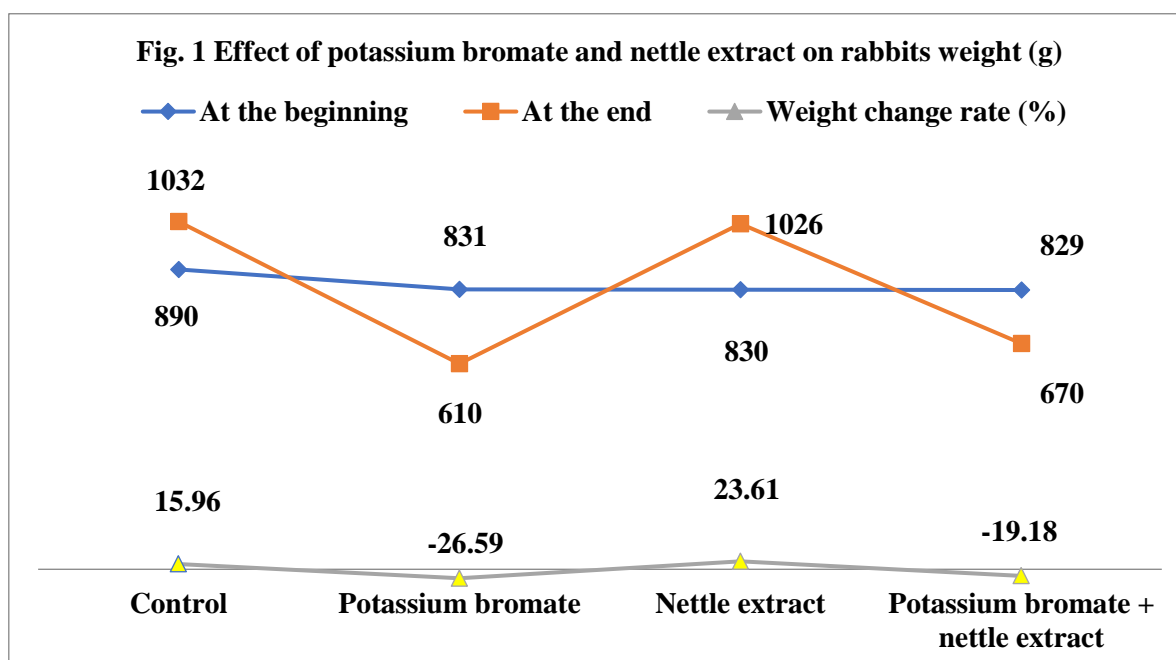


Fig. 1 Effect of potassium bromate and nettle extract on rabbits weight (g)

The findings in figure 3 revealed that the hormone testosterone levels in the blood increased when using nettle extract, reaching 30.45 ng /ml with an increase of 7.56% compared with the control. On the contrary, the use of potassium bromate has negative effects on the level testosterone, where its concentration, was reduced by 84.79% and 98.76% compared with control and exposure rabbits, respectively. On the other hand, the results showed that using nettle extract on rabbits that were previously dosed with potassium bromate led to an increase in the

testosterone level in the blood compared to those that were dosed with potassium bromate and were not treated with nettle extract, where increased from 15.32 to 28.01 ng/ml. These results were consistent with those explained by **Gheth *et al.*** in 2021, where they explained the negative effect of using potassium bromate on testosterone levels in the blood of mice. They concluded that reduced testosterone secretion was most likely caused by increased oxidative stress and the degradation of Leydig cells (**Jasim, 2024**).

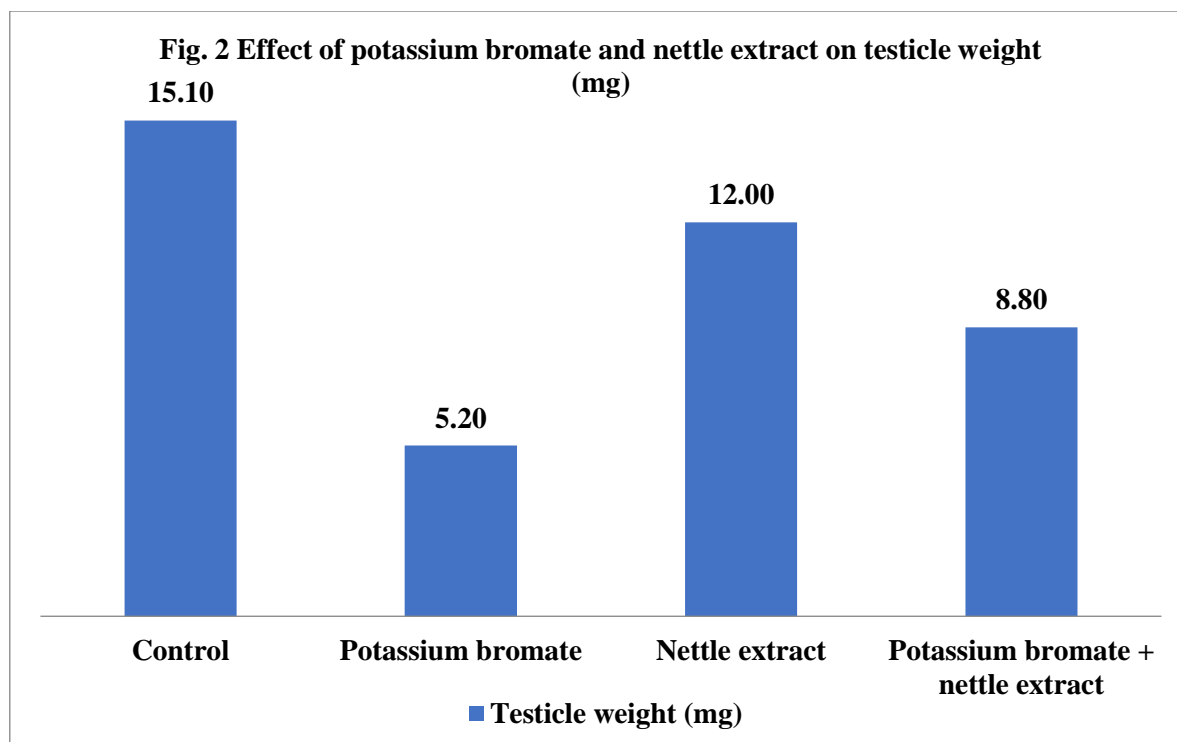


Fig. 2 Effect of potassium bromate and nettle extract on testicle weight (mg)

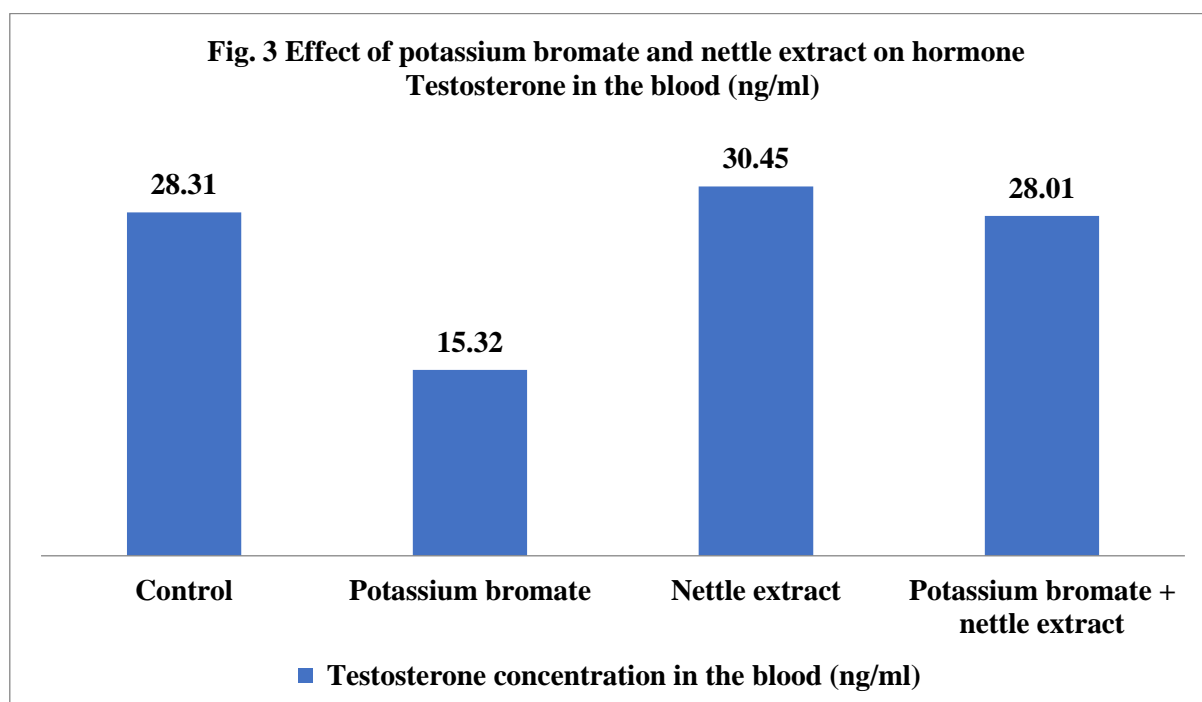


Fig. 3 Effect of potassium bromate and nettle extract on hormone Testosterone level in the blood (ng/ml)

Epididymal Sperm quality:

As rabbits were given potassium bromate, epididymal sperm motility, progressive motility, sperm count, and viability all decreased dramatically, also sperm cells with aberrant morphology increased significantly as

compared to control groups. In contrast, the use of nettle extract increased the concentration, quantity, and quality of sperm. On the other hand, the co-treatment with nettle extract reduces the harmful effect of potassium bromate while improving sperm quality.

Data in the following figure (4) showed that, the impact of potassium bromate and nettle extract on the count of sperm in rabbit semen. Where the rabbits were given potassium bromate, the sperm concentration in the semen reduced by 77.67% compared to the control group. While using nettle extract increased the quantity of sperm in rabbit semen by 25.06% and 122.18% compared to the control and potassium bromate groups, respectively. When using nettle extract with rabbits that were treated with

potassium bromate beforehand, it led to a relative improvement in the number of sperm in the semen compared to the group of rabbits that were treated with potassium bromate, as it increased by 55.52%.

These results are consistent with what **Elsheikh et al.**(2016), explained in experiments conducted on mice when potassium bromate was used in drinking water, which led to major deformities in the seminiferous tubules, which led to them being devoid of sperm.

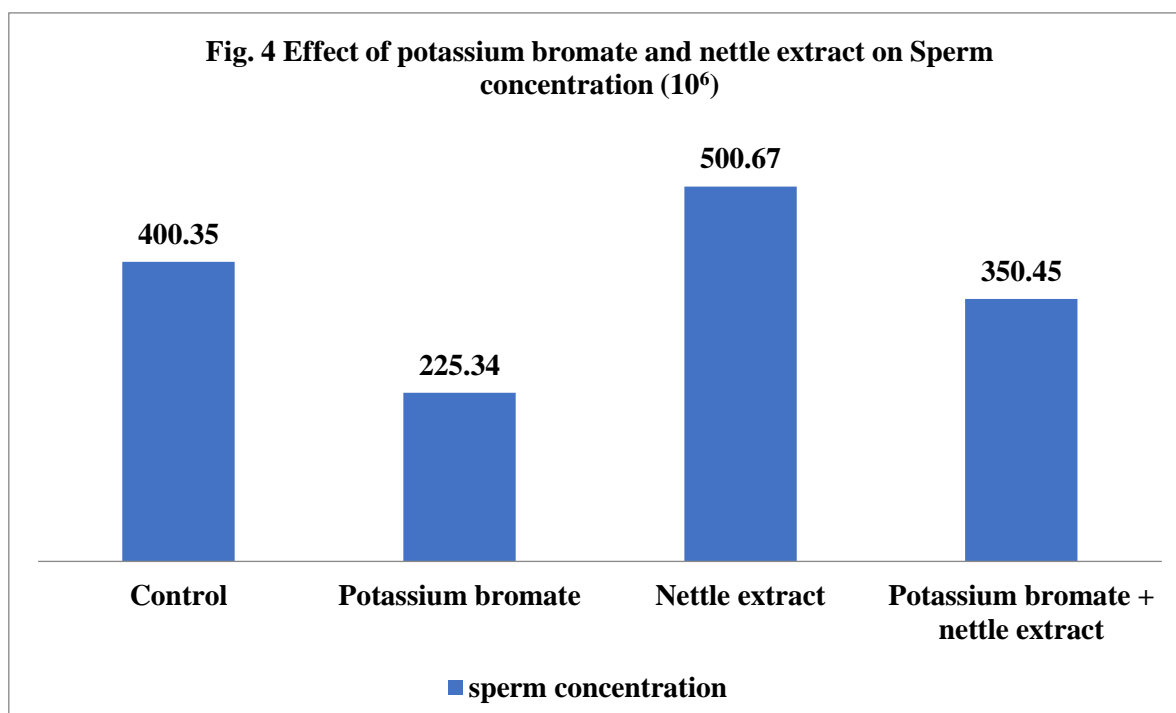


Fig. 4 Effect of potassium bromate and extract on sperm concentration in semen

The results in Table 1 showed that the exposure of animals to potassium bromate had a considerably lower sperm count, increased semen viscosity, led to motility distracted and random of sperm, and also led to abnormalities in the sperm, as the head became spherical and the tail short, fractured, and divided. But these perturbations were attenuated by using nettle extract. These results agreed with many studies; the effect of giving male rats dosages of potassium bromate was

examined in terms of morphological changes in sperm cells. Where reported, potassium bromate significantly led to an increase in sperm morphological abnormalities. Also, potassium bromate affected the number and motility of epididymis sperm and increased the incidence of defective sperm. This demonstrates how artificial food additives may have an impact on reproductive health (**Airaodion et al., 2022**).

Table 1 Effect of potassium bromate and nettle extract on epididymal sperm quality of rabbit samples

Treatment	Semen			
	Viscosity	Motility	Abnormalities	Count
Control	Natural	Natural and one-way	Natural, oval head, straight, movable tail	More 50
Potassium bromate	More viscous	Distracted and random	Head spherical, tail short, broken and divided	10
Nettle extract	Natural	Natural and one-way	Natural, oval head, straight, movable tail	More 50
Potassium bromate + Nettle extract	Less viscous	Natural and one-way	There are some deformities in the head.	Not less than 40

IV. DISCUSSION

Low epididymal weights are caused by growth retardation and azoospermia as a result of testicular hypoplasia. The histological sections of the testes indicated significant hypoplasia of the testicular structure as well as impaired spermatogenesis. These changes are likely owing to an iodine shortage caused by KBrO₃ supplementation in water. Iodine helps to decrease oxidative stress, a known factor that triggers germ cell death, because it neutralizes hydroxyl ions (Sahoo *et al.*, 2008). Furthermore, it is possible that potassium bromate altered the antioxidant activity of iodine and its carbon-bonded metabolites, as well as iodolactones, disrupting thyroid gland functions and reducing growth rate, epididymal, and testicular weights (Smyth *et al.*, 2009). The iodine deficit caused by potassium bromate may have impeded the manufacture of thyroid hormones, which are crucial for coordinating physiology within and between cells and tissues, and so impaired the growth and function of the gonads (Crockford, 2009). Potassium bromate causes iodine deficiency in the testes, making them sensitive to oxidative stress due to their high polyunsaturated fatty acid content and weak antioxidant defenses (Elsheikh *et al.*, 2016).

V. CONCLUSION

After assessing the effect of potassium bromate and nettle extract on the histological, physiological changes, and Epididymal sperm quality of the male reproductive organs of rabbits. The assessment showed that potassium bromate had a negative effect on testicular weight and semen quality and caused sperm abnormalities and reduced sperm count, while the use of nettles overcame these negative and toxic effects of potassium bromate administration for male rabbits.

REFERENCES

- [1] Adebisi, F. M., Ore, O. T., and Ojile, F. J. (2022). Evaluation of potentially toxic elements and bromate levels in bread commonly consumed in Nigeria for human health risk assessment. *Journal of Trace Elements and Minerals*, 2, 100016
- [2] Albadawi, E., El-Tokhy, A., Albadrani, M., Adel, M., El-Gamal, R., Zaarina, W., and Elsayed, H. R. H. (2024). The role of stinging nettle (*Urtica dioica* L.) in the management of rotenone-induced Parkinson's disease in rats. *Tissue and Cell*, 87, 102328
- [3] Airaodion, A. I., Chika-Igwenyi, N. M., Iwuoha, C. E., Agu, F. U., Nwobodo, M. U., Onyekachi, O. I. N., and Ezirim, E. O. (2022). Attenuation of potassium bromate-induced infertility by african locust bean (*Parkia biglobosa*) seed. *Asian Journal of Medicine and Health*, 20(11), 112-123.
- [4] Awoyemi, Z. O., Adigun, A. K., Awote, O. K., Igbalaye, J. O., Soares, A. S., and Oladimeji, S. O. (2022). Ethanolic Root Extract of *Urtica dioica* Exhibits Pro-fertility and Antioxidant Activities in Female Albino Rats. *International Journal of Biochemistry Research & Review*, 31(8), 29-38.
- [5] Crockford, S. J. (2009). Evolutionary roots of iodine and thyroid hormones in cell-cell signaling. *Integrative and comparative biology*, 49(2), 155-166.
- [6] Devkota, H. P., Paudel, K. R., Khanal, S., Baral, A., Panth, N., Adhikari-Devkota, A., and Hansbro, P. M. (2022). Stinging nettle (*Urtica dioica* L.): Nutritional composition, bioactive compounds, and food functional properties. *Molecules*, 27(16), 5219
- [7] Durak, I., Biri, H., Devrim, E., Sözen, S., and Avcı, A. (2004). Aqueous extract of *Urtica dioica* makes significant inhibition on adenosine deaminase activity in prostate tissue from patients with prostate cancer. *Cancer biology & therapy*, 3(9), 855-857.
- [8] Edirne, T., Arica, S. G., Gucuk, S., Yildizhan, R., Kolusari, A., Adali, E., and Can, M. (2010). Use of complementary and alternative medicines by a sample of Turkish women for infertility enhancement: a descriptive study. *BMC complementary and alternative medicine*, 10, 1-7.
- [9] Elsheikh, A. S., Fadul, T. F., Aboagla, E. M. E., and Gameel, A. A. R. (2016). Effects of potassium bromate on male rat growth and testicular histology. *Asian Pacific Journal of Reproduction*, 5(5), 376-38
- [10] Gupta, R., Singh, M., Kumar, M., Kumar, S., and Singh, S. P. (2014). Anti-osteoporotic effect of *Urtica dioica* on ovariectomised rat. *Indian Journal of Research in Pharmacy and Biotechnology*, 2(1), 1015
- [11] Gheth, E. M., Eldurssi, I. S., Hamad, M. A., Algassi, A. A., Abdalla, G. M., Aregeb, S. A., & Bolhaj, A. M. (2021). The Effect of Potassium Bromate on Testosterone Hormone in Rat's and Protective Role of *Ruta chalepensis* Oil Extract. *International Journal of Multidisciplinary Sciences and Advanced Technology, Special Issue*, 1(2020), 299-305.
- [12] Hajhashemi, V., and Klooshani, V. (2013). Antinociceptive and anti-inflammatory effects of *Urtica dioica* leaf extract in animal models. *Avicenna journal of phytomedicine*, 3(2), 193
- [13] Jalili, C., Salahshoor, M. R., and Naseri, A. (2014). Protective effect of *Urtica dioica* L against nicotine-induced damage on sperm parameters, testosterone and testis tissue in mice. *Iranian journal of reproductive medicine*, 12(6), 401
- [14] Klinefelter, G. R., Strader, L. F., Suarez, J. D., Roberts, N. L., Goldman, J. M., and Murr, A. S. (2004). Continuous exposure to dibromoacetic acid delays pubertal development and compromises sperm quality in the rat. *Toxicological sciences*, 81(2), 419-429
- [15] Leisegang, K. (2021). Herbal medicine used to treat andrological problems: Europe. *Herbal Medicine in Andrology*, 165-173.
- [16] Mohamed, N. S., Abdul-sattar, H., Ahmed, D., Esia, M., and Abd Alwahab, L. (2024). The Biological effects of urtica dioica extraction on some pathogenic Bacteria. *Journal of Pharmacology and Drug Development*, 2(2), 57-68

- [17] Nkwatoh, T. N., Fon, T. P., and Navti, L. K. (2023). Potassium bromate in bread, health risks to bread consumers and toxicity symptoms amongst bakers in Bamenda, North West Region of Cameroon. *Heliyon*, 9(2)
- [18] Patel, S. S., Ray, R. S., Sharma, A., Mehta, V., Katyal, A., and Udayabanu, M. (2018). Antidepressant and anxiolytic like effects of *Urtica dioica* leaves in streptozotocin induced diabetic mice. *Metabolic brain disease*, 33, 1281-1292
- [19] Roschek Jr, B., Fink, R. C., McMichael, M., and Alberte, R. S. (2009). Nettle extract (*Urtica dioica*) affects key receptors and enzymes associated with allergic rhinitis. *Phytotherapy Research: An International Journal Devoted to Pharmacological and Toxicological Evaluation of Natural Product Derivatives*, 23(7), 920-926
- [20] Sahoo, D. K., Roy, A., Bhanja, S., and Chainy, G. B. (2008). Hypothyroidism impairs antioxidant defence system and testicular physiology during development and maturation. *General and comparative endocrinology*, 156(1), 63-70.
- [21] Sahu, R., Saxena, M., and Mathur, H. B. (2016). Potassium bromate or potassium iodate in bread. *Centre for Science and Environment*.
- [22] Shanmugavel, V., Santhi, K. K., Kurup, A. H., Kalakandan, S., Anandharaj, A., and Rawson, A. (2020). Potassium bromate: Effects on bread components, health, environment and method of analysis: A review. *Food chemistry*, 311, 125964.
- [23] Smyth, P. P. A., Cloughley, G. C., Clarke, C., Smith, D. F., and Burbridge, E. (2009). Iodine and differentiated thyroid cancer: pathogenetic and therapeutic implications. *Hormones*, 8(3), 192-198.
- [24] Thomford, N. E., Dzobo, K., Chopera, D., Wonkam, A., Skelton, M., Blackhurst, D. and Dandara, C. (2015). Pharmacogenomics implications of using herbal medicinal plants on African populations in health transition. *Pharmaceuticals*, 8(3), 637-663.
- [25] Thompson, M. B. (1992). Clinical pathology in the National Toxicology Program. *Toxicologic Pathology*, 20(3-2), 484-489.
- [26] World Health Organization (2010), WHO laboratory manual for the examination and processing of human semen
- [27] Jasim, S. M. A. (2024, July). Testicular Tissue Injury and Sperms Abnormalities Induced by Potassium Bromate and the Ameliorative Effect of Sesame Oil in Male Rats. In *IOP Conference Series: Earth and Environmental Science* (Vol. 1371, No. 5, p. 052059). IOP Publishing.